



**PATIENT**

Jasmine Stello

**SPECIES**

Feline

**BREED**

DMH

**SEX**

FS

**AGE**

11 years

**WEIGHT**

14 #

**INTERPRETED BY**

Remo Lobetti, BVSc,  
MMedVet (Med),  
PhD, Dipl. ECVIM

**IMAGING  
PERFORMED BY**

Seth Mitchell, DVM

**HOSPITAL NAME**

Southside Veterinary  
Hospital

**REFERRING VET**

Dr Kilpatrick

**INVOICE**

302640

**DATE**

11/17/21

**PRESENTING CLINICAL SIGNS**

History: Intermittent nausea unrelated to eating.

Physical Examination: N/A.

Urinalysis: N/A.

CBC: Mild neutrophilia.

Serum Biochemistry: Normal.

Radiographic Findings: Concretions within the stomach.

**ULTRASONOGRAPHIC EXAMINATION OF THE ABDOMEN**

**Urinary System**

Full urinary bladder with a normal thickness and appearance of the wall. Normal anechoic urine with no sediment or uroliths evident.

Normal trigone area, proximal urethra and iliac blood vessels.

Normal iliac lymph nodes. Ureters not visualized.

Normal renal size (both 4 cm), echogenic appearance, cortico-medullary differentiation, capsule, and pelvis.

**Reproductive System**

N/A.

**Adrenal Glands**

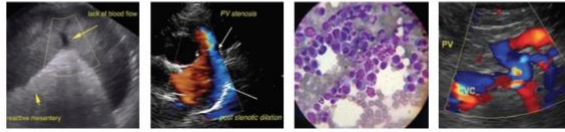
Normal shape, echogenic appearance, size, and position. Left 0.42 cm, right 0.43 cm.

**Spleen**

Normal size and echogenic appearance. Smooth homogenous parenchyma, smooth curvilinear capsule, and normal vasculature. No evidence of inflammatory, neoplastic, infarction, or infiltrative changes noted.

**Liver**

Normal size, echogenic appearance, and portal markings. No nodules or masses evident. Small gall bladder containing normal anechoic bile. Normal appearance and thickness of the gall bladder wall. Normal bile duct.



**PATIENT**

Jasmine Stello

**SPECIES**

Feline

**BREED**

DMH

**SEX**

FS

**AGE**

11 years

**WEIGHT**

14 #

**INTERPRETED BY**

Remo Lobetti, BVSc,  
MMedVet (Med),  
PhD, Dipl. ECVIM

**IMAGING PERFORMED BY**

Seth Mitchell, DVM

**HOSPITAL NAME**

Southside Veterinary  
Hospital

**REFERRING VET**

Dr Kilpatrick

**INVOICE**

302640

**DATE**

11/17/21

***Gastrointestinal***

Normal appearance of the gastro-esophageal junction, stomach, ileo-cecal junction, and colon with no loss of layering, normal wall thickness and peristalsis, and no distension of the lumen. Thickening of the duodenum (0.4 cm) and jejunum (0.5 cm) but with no loss of layering or distension of the lumen.

***Pancreas***

Normal size and echogenic appearance. Normal echogenic appearance of the mesentery and fat surrounding the pancreas.

***Free Abdomen***

Mesenteric lymphadenomegaly (0.8 cm) with normal shape and echogenic appearance. No ascites.

**ULTRASONOGRAPHIC FINDINGS**

Primary findings:

- Enteropathy.
- Mesenteric lymphadenomegaly.

Secondary findings:

- None.

**INTERPRETATION OF THE FINDINGS & FURTHER RECOMMENDATIONS**

Etiologies for the enteropathy would be parasitic enteritis, inflammatory bowel disease, dietary hypersensitivity, and emerging lymphoma.

Etiologies for the lymphadenomegaly would be reactive, lymphadenitis, and lymphoma.

Further assessment would be fecal analysis, cobalamine assay, and endoscopy of the upper GI tract with biopsies.

Specific therapy would be dependent on an etiological diagnosis. Symptomatic management of the enteropathy would be hypoallergenic/novel protein diet, course of metronidazole and/or fenbendazole, and possibly prednisolone.



**PATIENT**

Jasmine Stello

**SPECIES**

Feline

**BREED**

DMH

**SEX**

FS

**AGE**

11 years

**WEIGHT**

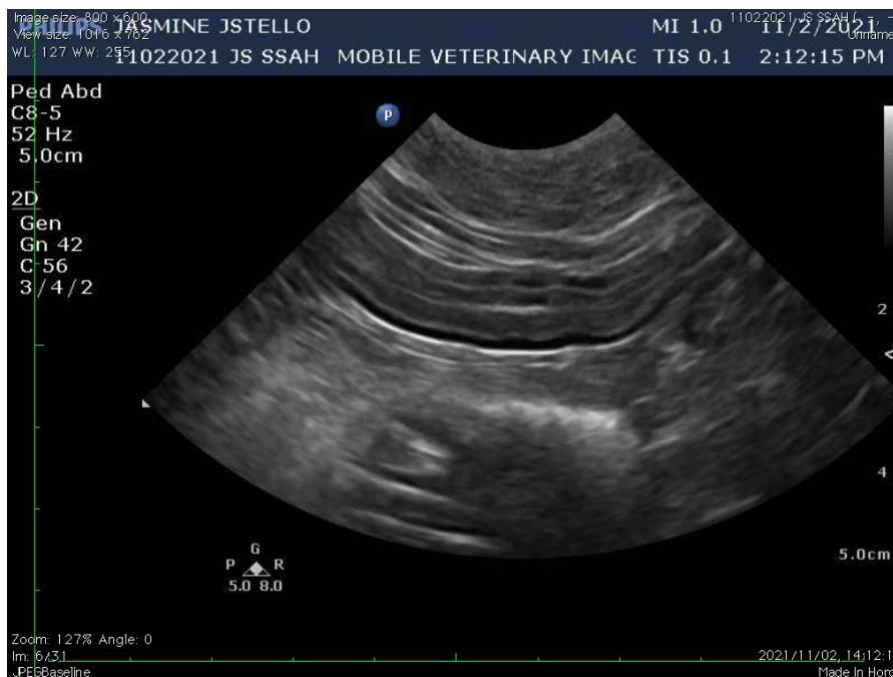14 #

**INTERPRETED BY**

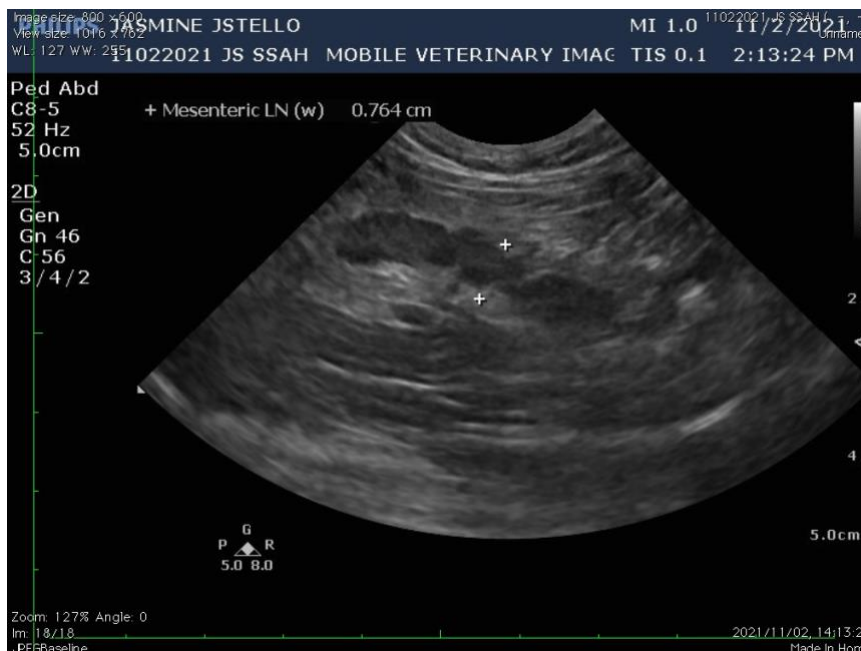Remo Lobetti, BVSc,  
 MMedVet (Med),  
 PhD, Dipl. ECVIM

**IMAGES**

**Small intestine**



**Mesenteric lymph node**



**IMAGING PERFORMED BY**

Seth Mitchell, DVM

**HOSPITAL NAME**

Southside Veterinary  
 Hospital

**REFERRING VET**

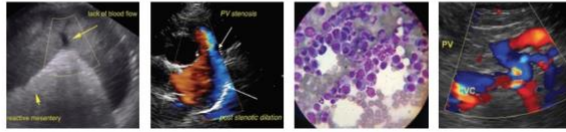
Dr Kilpatrick

**INVOICE**

302640

**DATE**

11/17/21



**PATIENT**

Jasmine Stello

**SPECIES**

Feline

**BREED**

DMH

**SEX**

FS

**AGE**

11 years

**WEIGHT**

14 #

**The information and recommendations provided are based on the images presented by the referring veterinarian. No evaluation can be communicated regarding pathology that was not visible in the image/video clips provided.**

Thank you for this referral. If the clinical or image interpretation does not parallel your findings or if I can be of any further assistance please contact me.

**Remo Lobetti, BVSc, MMedVet (Med), PhD, Dipl. ECVIM (Internal Medicine)**  
rlobetti@mweb.co.za

**INTERPRETED BY**

Remo Lobetti, BVSc,  
MMedVet (Med),  
PhD, Dipl. ECVIM

**IMAGING PERFORMED BY**

Seth Mitchell, DVM

**HOSPITAL NAME**

Southside Veterinary  
Hospital

**REFERRING VET**

Dr Kilpatrick

**INVOICE**

302640

**DATE**

11/17/21